

Patient ID : GScanlon052299
 Procedure : OCTReport
 Eye : OS(L)

Patient Name : Scanlon Graham
 Create Date : 12/30/2025
 Timer :

Print Date : 12/30/2025

TOPCON 3D Wide Report

Print Date: 12/30/2025

ID: GScanlon052299

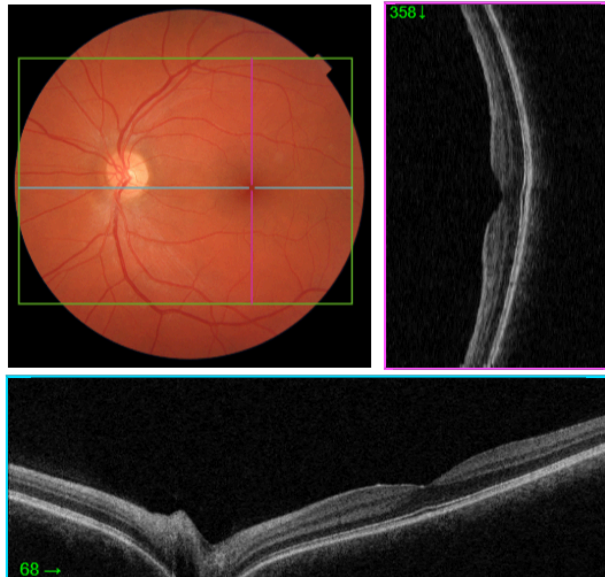
Ethnicity:
 Gender:
 DOB: 05/22/1999 Age: 26

Technician:
 Fixation: Wide
 Scan: 3D(12.0x9.0mm - 512x128)

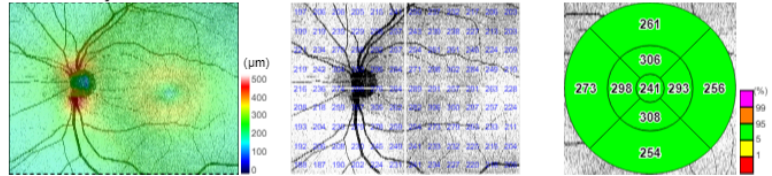
Maestro2

Name: Graham Scanlon

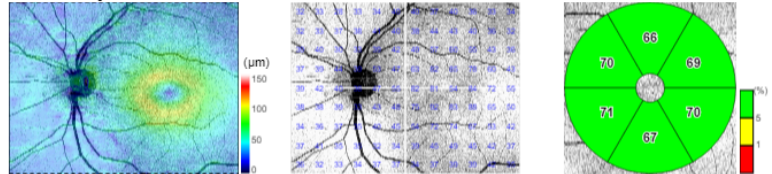
OS Image Quality: **42** Analysis mode: Fine (2.0.8)
 Capture Date: 12/30/2025



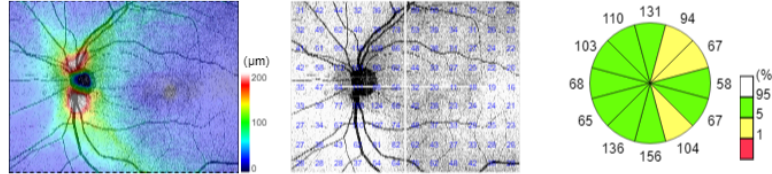
Retina Analysis



GCL+ Analysis

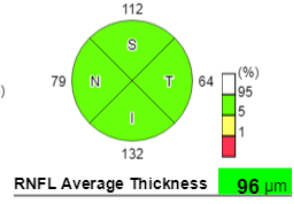
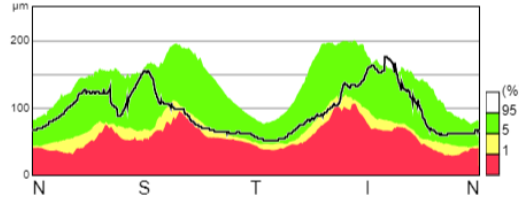
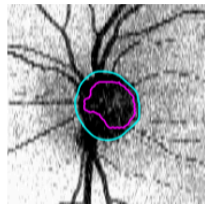

RNFL Analysis



Disc Topography

Rim Area (mm ²)	0.86
Disc Area (mm ²)	1.71
Linear CDR	0.71
Vertical CDR	0.69
Cup Volume (mm ³)	0.14



Reference Plane Height: 120µm
 Comments:

Signature:

Date: